Investigation of Cause of Abnormal Uterin Bleeding in Postmenopusal women : A review study

Samaneh Dabagh Fekri*[1] , Shiva Irani[2], Firouzeh Asadzadeh[3]

MSc in Midwifery, Department of Midwifery, School of Nursing and Midwifery, Ardabil University of Medical Sciences, Ardabil, Iran , Email: fekrisamane@gmail.com

Background and Aim

Abnormal uterin bleeding (AUB) is a common gynecologic problem in postmenopusal women. It can be caused by uterine abnormalities or due to other reasons. Any bleeding with excessive duration, frequency and amount is AUB that occur based on the several etiology: polyp; malignancy; coagulopathy; iatrogenic; etc. ACOG recomends endometrial sampeling as first diagnostic test in women with AUB who are older than 45 years. The aim of this study was to Investigat the cause of abnormal uterin bleeding in postmenopusal women.

.

Materials and Methods

This study was a simple review and reasons of abnormal uterin bleeding in postmenopusal women was investigated from 2009-2019 using several databases including Cochrane, *Scopus*, Medline, Web of Science, Embase, Google Scholar, Iran medex, and Scientific Information Database with keywords: AUB; postmenopusal bleeding and menopause. 14 articles were selected based on the research criteria.

Results

Results showed that the most common finding in Postmenopusal women with AUB was atrophic endometrium. Other commen causes were hyperplastic endometrium; endometrial carcinoma and endometrial polyp, respectively. The most abnormal pathologies were seen in women with diabetes, hypertension and hypothyroidism.

Conclusion

The results of the present study underscore endometrial sampling should be performed to detect endometrial cancer and hyperplasia in postmenopausal women with AUB, specially in women who are 60< and with endometrial volume ≥3 ML. In all cases with postmenopausal bleeding, focal lesions and endometrium 5 mm≤ operative hysteroscopy should be performed.

Keywords: Abnormal uterin bieeding, Postmenopusal bleeding, Menopause.

reference

Karsidag AY, Buyukbayrak EE, Kars B, Unal O, Turan MC. Transvaginal sonography, sonohysterography, and hysteroscopy for investigation of focal intrauterine lesions in women with recurrent postmenopausal bleeding after dilatation & curettage. Archives of gynecology and obstetrics. 2010 Apr 1;281(4):637-43.

Telner DE, Jakubovicz D. Approach to diagnosis and management of abnormal uterine bleeding. Canadian Family Physician. 2007 Jan 1;53(1):58-64.
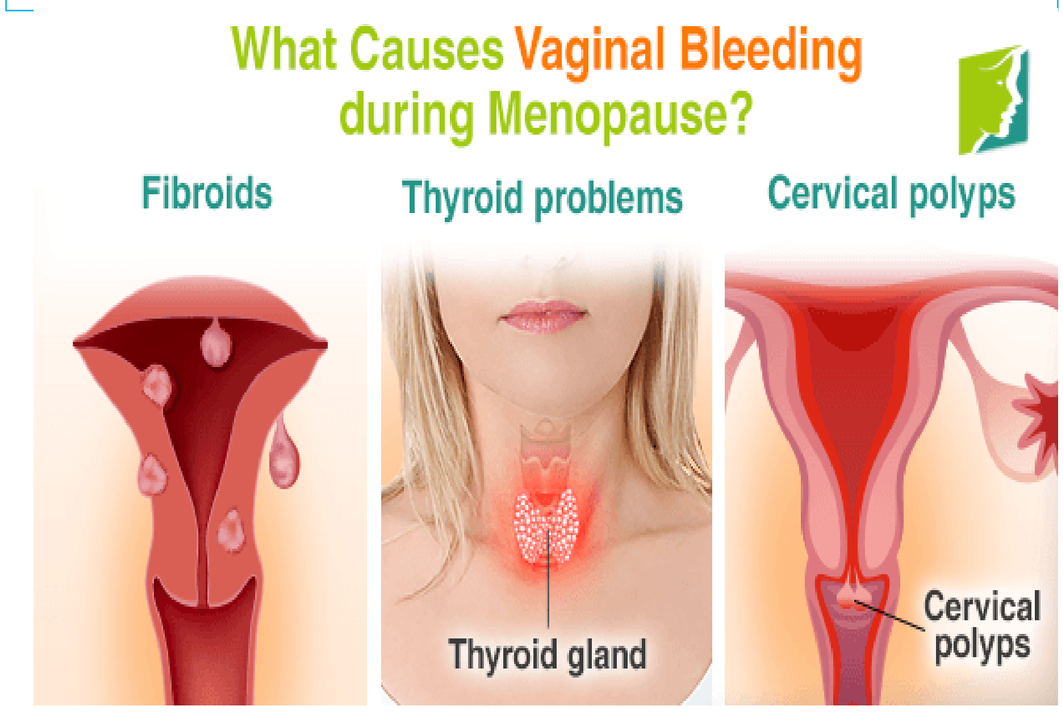
Maia Jr H, Maltez A, Oliveira M, Calmon LC, Coutinho EM. Diagnosis and treatment of abnormal uterine bleeding in postmenopausal patients using hormone replacement therapy. Gynaecological Endoscopy. 2002 Dec;7(6):319-25.