

See discussions, stats, and author profiles for this publication at: <https://www.researchgate.net/publication/330292140>

The Ameliorative Effect of Galega officinalis Extract on Histological Damages, Oxidative Stress Induced by Torsion–Detorsion in Adult Rats’ Ovarian

Article in *International Journal of Women's Health and Reproduction Sciences* · January 2019

DOI: 10.15296/ijwhr.2019.19

CITATIONS

3

READS

84

4 authors, including:



Majid Shokoohi

Tabriz University of Medical Sciences

38 PUBLICATIONS 266 CITATIONS

SEE PROFILE

Some of the authors of this publication are also working on these related projects:



Testicular torsion [View project](#)



Testicular torsion [View project](#)



The Ameliorative Effect of *Galega officinalis* Extract on Histological Damages, Oxidative Stress Induced by Torsion-Detorsion in Adult Rats' Ovarian

Farnaz Shokri¹, Majid Shokoohi^{2*}, Ayda Roudi Rasht Abadi³, Hossein Kalarestaghi⁴

Abstract

Objectives: The antioxidative role of *Galega officinalis* extract has been reported in several studies. However, this experimental study was designed in order to investigate the impacts of *G. officinalis* extract against parameters, such as histological, hormonal, and oxidative stress parameters, which were induced by ovarian torsion/detorsion.

Materials and Methods: Adult female Wistar rats (n = 28) were randomly divided into 4 groups including sham (G1), ovarian torsion for 3 hours then-after detorsion (G2 or TD), ovarian torsion-detorsion orally received 50 mg/kg extract of *G. officinalis* (G3 or TDGO), healthy rats orally received 50 mg/kg hydroalcoholic extract of *G. officinalis* (G4 or GO). Ten days after torsion-detorsion, rats were sacrificed and their ovaries, and their blood levels of hormones including estrogen and testosterone, as well as some oxidative stress markers were assayed.

Results: The structure of ovaries in TD groups of the study showed a notable change compared to other groups. The serum levels of superoxide dismutase (SOD) and glutathione peroxidase (GSH), and also estrogen significantly decreased in TD group, while treatment with *G. officinalis* could prevent from decreasing mentioned parameters. Furthermore, although torsion-detorsion led to increasing the serum level of malondialdehyde (MDA), it was decreased after administration of *G. officinalis*.

Conclusions: Obtained results showed that *G. officinalis* could be useful in elevating the estrogen level, reducing the oxidative stress marker (i.e. MDA) and ovarian tissue damages induced by torsion-detorsion.

Keywords: Torsion-detorsion, Ovarian tissue, *Galega officinalis*, Oxidative stress markers, Steroidal hormones

Introduction

Ovarian torsion is one of the most commonly gynecologic emergencies in all age groups and also about 3% of women's emergency cases. In this condition, usually an ovary twist around their ligaments which hold it in its normal place. Hence, this condition can lead to cutting off the blood flow to the uterine tube (oviduct) and the ovary (1). Accurate diagnosis and management of ovarian torsion is important, especially for women who are in childbirth age (2,3)

Detorsion or opening the twist is one of the interventions that are performed to prevent ovarian tissue loss (3). Torsion followed by detorsion or ischemia-reperfusion is a pathophysiologic event that firstly results to reduction of oxygen in ovarian tissue (ischemia), then, after detorsion (reperfusion), results to elevating inflammatory cytokines that lead to injury of endothelial cells of vessel and microcirculation disorders that are mostly responsible for the damage to the ovary tissue (3-6). On the other hand, the ischemia-reperfusion damage led to over generation of reactive oxygen species (ROS) such as hydroxyl free radical species, hydrogen peroxide (H₂O₂), and superoxide (O₂⁻) (3-6).

Considering the effects of oxidation on ovarian damage caused by torsion/detorsion, the use of antioxidants plays an important role in healing; moreover, undesirable effects of antioxidants are recommended in recent research as a conservative approach (7). *Galega officinalis* is known as *Galega* belonging to the *Fabaceae* family that grows in southeastern parts of Europe as well as the Middle East (8-11). It has been reported that *G. officinalis* has been used as a supplement for treating diabetes mellitus in the Medieval period (8,12). The hydroalcoholic extract of *G. officinalis* contains flavonoids, tannins, saponins, glycosides, resins, and steroids. However, these compounds (alkaloids, flavonoids, and phenols) have antioxidant properties (9,13).

However, the main purpose of the present study was to investigate the protective effect of hydroalcoholic extract of *G. officinalis* on torsion-detorsion induced damages in the ovarian tissue.

Materials and Methods

Designing of the Experiment

Purchased adult female Wistar rats (n = 28, weighting = 180-200 g) were housed in the animal room of Tabriz

Received 10 November 2017, Accepted 8 November 2018, Available online 25 November 2018

¹Women's Reproductive Health Research Center, Tabriz University of Medical Sciences, Tabriz, Iran. ²Department of Anatomical Sciences, Faculty of Medicine, Tabriz University of Medical Sciences, Tabriz, Iran. ³Department of Animal Biology, Faculty of Biology, University of Kharazmi, Tehran, Iran. ⁴Department of Anatomy and Pathology, Research Laboratory for Embryology and Stem Cell, Faculty of Medicine, Ardabil University of Medical Sciences, Ardabil, Iran.

*Corresponding Author: Majid Shokoohi, Tel: +989158009047, Email: a.shokoohy@yahoo.com



University of Medical Sciences, under the standard conditions (12/12 light/dark cycle, 25°C), while had free access to water and food. However, all rats were randomly divided to 4 groups (n = 8/group) including:

1. Sham group (G1), in the midline region of the lower abdomen, a linear longitudinal incision (2.5 cm) was made, then it was closed using 6/0 nylon sutures.
2. Group 2 (G2 or TD), torsion was induced in left ovary and it remained for 3 hours. Then, 30 minutes before detorsion operation, rats received normal saline.
3. Group 3 (G3 or TDGO), ovarian torsion was induced as same as group 2. Then, 30 minutes before detorsion operation, rats orally received 50 mg/kg hydroalcoholic extract of *G. officinalis*.
4. Group 4 (G4 or GO), in this group, all rats only received 50 mg/kg hydroalcoholic extract of *G. officinalis* without receiving any operation.

Operation

Selected rats for torsion-detorsion surgery were anesthetized with xylazine/ketamine (1/5 mg/kg) (4-7). Then, lower part of the abdomen was longitudinally opened and the left ovary rotated 720° in clockwise direction (7). Afterwards, in order to keep the torsion situation, it was fixed to the posterior wall of the abdomen using nylon sutures (6/0) (7). In the second step, 3 hours after torsion induction, an operation for detorsion was carried out and left ovary was fixed in normal position as same as described. In the treated torsion-detorsion group, 30 minutes before detorsion operation, rats orally received the hydroalcoholic extract of *G. officinalis*. The duration of treatment was 10 days, then, at the end of the study, all rats were anesthetized as same as described, then their bloods were taken to assess the changes in hormonal and antioxidant levels. Hence, bloods were centrifuged (5 minutes, 3000 RPM), then each plasma of samples was isolated and frozen in -70°C until the time of the experiment.

Histological Study

In order to fixation of ovaries, firstly, they were placed in formalin (10%) for 72 hours, then, after dehydration stage, all samples embedded in paraffin, sections with thickness 5 µm were prepared, and staining was performed using the solution of hematoxylin and eosin (H&E). To assessment the histological and histometrical parameters, each ovary section in the clockwise direction inquired from the cortex to the medulla (7). However, the number of follicles in all stages such as primordial, primary, antral, and graafian stages was calculated. Furthermore, the number of atretic and yellow bodies was counted.

Assessing the Oxidative Stress Markers

The level of malondialdehyde (MDA) in plasma was assessed based our previous studies (5,6,14). However, 0.2 mL of serum was poured into a microtube which

had incubated with 3 mL glacial acetic acid. Then, 1% thiobarbituric acid (TBA) in 2% NaOH was added to the microtube. After boiling stage (15 minutes), the absorbance of the product was read at 532 nm. Moreover, the levels of superoxide dismutase (SOD) and GSH peroxidase (GPx) in the plasma were measured according to the manufacturer's instructions (Randox, and Ransod, UK; sensitivity <S1 standard value) using an Elisa reader device (Antus) (4,5).

Measuring the Plasma Levels of Estrogen and Testosterone

The plasma levels of hormones, estrogen and testosterone, were determined by an enzyme-linked immunosorbent assay (ELISA) kit (Demeditec Diagnostics, Germany) and the absorbances were measured at 405 nm.

Statistical Analysis

For statistical analysis, software SPSS 20 (IBM, USA) was used. All data of this study were presented as mean ± standard error (SE). Firstly, the Kolmogorov-Simonov test was performed whether data are normal. One-way ANOVA followed by Tukey post hoc test was accomplished to compare the values of the mentioned parameters. $P < 0.05$ was considered as statistically significant.

Results

Histological Assessment

Table 1 shows that the number of follicles at primary stage was notably decreased in the TD group as when compared to G1 ($P < 0.05$). In addition, a significant difference between torsion-detorsion group and the other groups was observed ($P < 0.05$). The number of antral follicles was remarkably diminished in the TD group relative to G1 ($P < 0.05$). In TDGO and GO groups, the number of antral follicles was enhanced notably in comparison with G2 ($P < 0.05$).

The number of graafian follicles was remarkably decreased in the TD group when compared to the G1 ($P < 0.05$). But, it was enhanced in the treated groups, TDGO and GO, compared to the TD group ($P < 0.05$). A comparison between all groups of the study also showed that the number of atretic bodies was remarkably increased in the torsion-detorsion relative to the G1 ($P < 0.05$). However, in the treated group with *G. officinalis* (TDGO), the number of atretic bodies was significantly decreased in comparison with TD group ($P < 0.05$). On the other hand, in the TD group, the number of yellow bodies was significantly decreased in comparison with G1 ($p < 0.05$), while in the treated groups, TDGO and GO, it was remarkably increased relative to the TD group ($P < 0.05$) (Table 1 and Figure 1).

Levels of Hormones, Estrogen and Testosterone

Figures 2 and 3 show the levels of estrogen and testosterone hormones. According to them, the level of testosterone was significantly increased in the TD group compared to

Table 1. The Mean Number of Follicles, Atretic and Yellow Bodies in the Rat's Ovaries

Group	Primordial Follicles	Primary Follicles	Antral Follicles	Graafian Follicles	Atretic Bodies	Yellow Bodies
Sham	7.2 ± 2.52	6.92 ± 1.32	5.7 ± 0.42	5.5 ± 0.61	1.6 ± 0.11	5.5 ± 0.27
TD	1.2 ± 1.05*	1.07 ± 0.72*	1.23 ± 0.72*	1.2 ± 0.21*	6.2 ± 0.51*	2.01 ± 0.41*
TDGO	4.4 ± 1.3†*	4.5 ± 1.36†	4.03 ± 1.2†	3.82 ± 0.74†	3.2 ± 0.34†	4.7 ± 0.34†
<i>G. officinalis</i>	7.5 ± 1.3†	6.52 ± 1.70†	5.9 ± 1.5†	5.2 ± 0.62†	1.2 ± 0.24†	5.9 ± 0.82†

Sham; sham group, TD; ovarian torsion for 3 h that receiving normal saline by oral gavage, 30 min before detorsion and followed by detorsion for 10 days, TDGO; ovarian torsion for 3 h that receiving 50 mg/kg hydroalcoholic extract of *G. officinalis* for 10 days (daily), 30 min before detorsion and followed by detorsion for 10 days, *G. officinalis*; all rats received 50 mg/kg hydroalcoholic extract of *G. officinalis* 10 days (daily). All data are displayed as mean ± SEM. The asterisk * shows significant difference with the sham group and the symbol of † means the significant difference with the TD group. ($P < 0.05$)

G1 ($P < 0.05$).

The plasma testosterone level was importantly enhanced in the TD group compared to sham ($P < 0.05$). A significant reduction in the plasma level of testosterone was observed in treated groups ($P < 0.05$).

On the other hand, the plasma level of estrogen was remarkably declined in the TD group when compared to G1 ($P < 0.05$). Moreover, it was increased in TDGO and GO groups, compared to G2 ($P < 0.05$).

Levels of Oxidative Stress Markers

The levels of SOD and GPx were significantly decreased in TD group relative to G1 ($P < 0.05$), while in the torsion-detorsion group, the level of MDA was higher than those of treated groups ($P < 0.05$). On the other hand, treatment with *G. officinalis* could decrease the level of MDA and increase the levels of SOD and GPx compared to the TD group ($P < 0.05$) (Table 2).

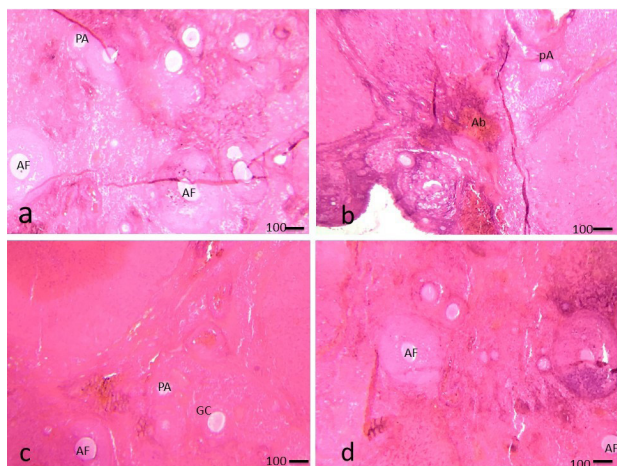


Figure 1. Histological Examinations in Study Group 10 Days After Surgery.

(a); sham group, TD (b); ovarian torsion for 3 h that receiving normal saline by oral gavage, 30 min before detorsion and followed by detorsion for 10 days, TDGO (c); ovarian torsion for 3 h that receiving 50 mg/kg hydro alcoholic extract of *G. Officinalis* for 10 days (daily), 30 min before detorsion and followed by detorsion for 10 days, *G. Officinalis* (GO) (d); all rats received 50 mg/kg hydro alcoholic extract of *G. Officinalis* 10 days (daily). All data are displayed as Mean±SEM. AF: Antral follicle; PA: Preantral follicle; GC: Granulosa cell; Ab: Atretic body.

Discussion

The reproductive life of women or even thereafter can be affected by oxidative stress (5,6,15,16). Oxidative stress has been considered as an inconsistency between the generation of ROS and antioxidant defense capability of the body

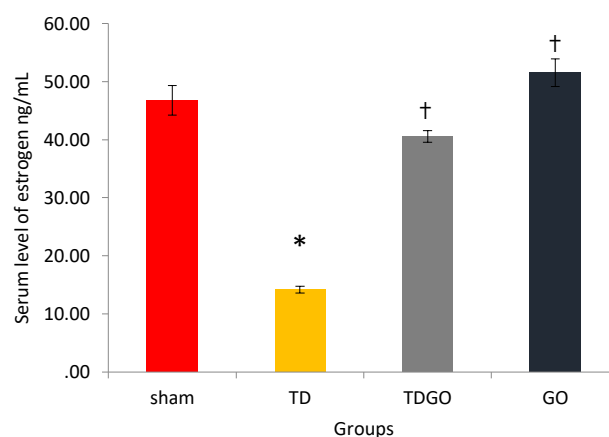


Figure 2. Comparison the Serum Level of Estrogen in Different Groups. The asterisk * shows significant difference with the sham group and the symbol of † means the significant difference with the TD group ($P < 0.05$)

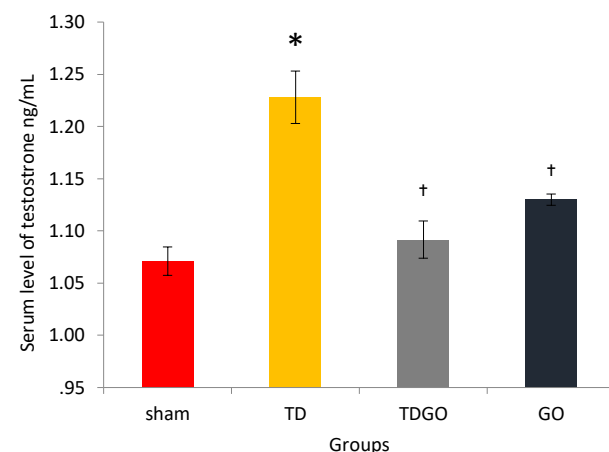


Figure 2. Comparison the Serum Level of Testosterone in Different Groups. The asterisk * shows significant difference with the sham group and the symbol of † means the significant difference with the TD group ($P < 0.05$)

Table 2. The Oxidative Stress Markers in All Groups of the Study

Groups	SOD (Mean ± SEM)	GPX	MDA (Mean ± SEM)
Sham	1.97 ± 0.11	20.53 ± 5.11	1.38 ± 0.11
TD	0.89 ± 0.09*	8.74 ± 2.32*	2.82 ± 0.29*
TDGO	1.55 ± 0.17†	15.24 ± 4.21†	1.53 ± 0.21†
<i>G. officinalis</i>	2.01 ± 0.08†	20.76 ± 4.08†	1.32 ± 0.24†

Sham; sham group, TD; ovarian torsion for 3 h that receiving normal saline by oral gavage, 30 min before detorsion and followed by detorsion for 10 days, TDGO; ovarian torsion for 3 h that receiving 50 mg/kg hydroalcoholic extract of *G. officinalis* for 10 days (daily), 30 min before detorsion and followed by detorsion for 10 days, *G. officinalis*; all rats received 50 mg/kg hydroalcoholic extract of *G. officinalis* 10 days (daily). All data are displayed as mean ± SEM. The asterisk * shows significant difference with the sham group and the symbol of † means the significant difference with the TD group. ($P < 0.05$)

(4-7,9,14,15,17). The function of ROS has a similarity to the double-edged sword; one of their activities involves in body physiological processes as key signal molecules, but ROS have the main role in pathological damage in the reproductive system (15,16,18). For instance, in many physiological processes such as oocyte maturation, fertilization, development of embryo, as well as pregnancy, ROS are effective (15-17).

In the present study, ovarian torsion increased oxidative stress, then resulted in tissue damage in the ovary. Our results also showed that torsion-detorsion led to decreasing the number of follicles in all stages, including primordial, primary, antral, and graafian stages, as well as the number of yellow bodies, while the number of atretic bodies increased. These findings can be contemplated as a tissue inconvenience. In agreement with our results, Agarwal et al reported that the numbers of primordial, primary, antral, and graafian follicles significantly decrease when the level of ROS increases (16). Furthermore, Soltani et al showed that ovarian torsion-detorsion could result in a reduction in the number of follicles in all mentioned stages (7).

Oxidative stress has a destructive effect on DNA, therefore it is the base of injury in the epithelium of ovary and ovulation (7,16). Several studies have shown that oxidative stress can play an important role in the pathophysiology of infertility (4,5,7,16,19,20). On the other hand, ischemia-reperfusion injury in the ovary could be considered as the main source of ROS generation (5,7). However, as a matter of fact, oxidative stress can also be barricaded by antioxidant components (14,21).

Obtained results of the present study showed that ovarian torsion-detorsion increased the serum level of testosterone while decreased the serum level of estrogen. On the other hand, ovarian torsion-detorsion also decreased the levels of antioxidant parameters, SOD and GPX, while it was led to an elevation in oxidative stress marker, MDA. Hence, we can conduct that antioxidant defense systems were not able to decrease the level ROS. Agarwal et al contend that overproduction of ROS results

in decreasing the estrogen level, diminishing in the levels of SOD and GPX, and increasing the level of MDA (16). Moreover, Túnez et al reported that oxidative stress can enhance the testosterone level in female rats (22). Also, Celik et al showed that ovarian rotation for 3 hours and followed by detorsion can decrease the GPx level and elevate the level of MDA (23). In another study, Soltani et al claimed ovarian torsion for 3 hours and afterwards detorsion decreased the levels of SOD and GPx, while elevating the level of MDA; moreover, ovarian torsion-detorsion could lead to hormonal damage, such as a reduction in estrogen level and an in testosterone level (7).

In hindering the overgeneration of ROS, antioxidant mixtures can be efficient, hence, they can be used to overcome infertility disorders associated with oxidative stress (15,16). *G. officinalis* contains flavonoids, tannins, saponins, glycosides, resins, and steroids (9,13). These compounds (alkaloids, flavonoids, and phenols) have antioxidant properties (9,13). The antioxidant, antibacterial, and anti-inflammatory properties of *G. officinalis* have been reported (8,9,13).

Therefore, due to this fact that *Galega* has flavonoid and alkaloid components, it can be considered as a potent antioxidant for inhibiting the generation of free radicals and lipid peroxidation (11,13).

In this study, the hydroalcoholic extract of *G. officinalis* could prevent from ROS production and oxidative stress, hence, the number of follicles and yellow bodies increased, while the number of atretic bodies decreased. In one study, it has been reported that 10 days treatment with *G. officinalis* could lead to increasing numbers of follicles (9).

The hydroalcoholic extract of *Galega* could elevate the reduced level of estrogen in rats which underwent on torsion-detorsion. Moreover, in torsion-detorsion rats that treated with *G. officinals*, the elevated testosterone level decreased. However, it has been reported that administration of *G. Officials* for 10 days could decrease the level of testosterone and increase the level of estrogen (9).

In this study, treatment with *G. officinals* could elevate the serum levels of antioxidant parameters such as SOD and GPX, while decreasing the level of MDA in the serum and preventing from lipid peroxidation. These happenings may be due to the antioxidant compounds in *G. officinalis* extract (9,13).

Conclusions

The results of the present research revealed the *G. officinalis*, as a hydroalcoholic source, could regulate the levels of sexual hormones and protect the ovarian tissue against oxidative stress and tissue injury that induced by ovarian torsion/detorsion.

Study limitation

Inability to carry out this project on a clinical basis in patients with ovarian torsion is the main limitation of the study.

Conflicts of Interests

The authors declare no conflict of interest in this study.

Ethical Issues

The ethical committee of Tabriz University of Medical Sciences approved the study. (Ethics No. IR.TBZMED.VCR.REC.1397.126).

Financial Support

Tabriz University of Medical Sciences supported the study.

Acknowledgments

Authors would like to thank from Deputy of Research and Technology of Tabriz University of Medical Sciences for financial support of this study.

References

- Navve D, Hershkovitz R, Zetounie E, Klein Z, Tepper R. Medial or lateral location of the whirlpool sign in adnexal torsion: clinical importance. *J Ultrasound Med.* 2013;32(9):1631-4. doi: 10.7863/ultra.32.9.1631.
- Kazem A, Ozel S, Akpolat N, Goksu M. The efficacy of conservative treatment for late term ovarian torsion. *Eur J Pediatr Surg.* 2007;17(02):110-4.
- Huang C, Hong M-K, Ding D-C. A review of ovary torsion. *Tzu-Chi Med J.* 2017;29(3):143.
- Shokoohi M, Madarek EOS, Khaki A, et al. Investigating the effects of onion juice on male fertility factors and pregnancy rate after testicular torsion/detorsion by intrauterine insemination method. *Int J Womens Health Reprod Sci.* 2018;6(4):499-505. doi:10.15296/ijwhr.2018.82
- Shokoohi M, Shoorei H, Soltani M, Abtahi-Eivari SH, Salimnejad R, Moghimian M. Protective effects of the hydroalcoholic extract of *Fumaria parviflora* on testicular injury induced by torsion/detorsion in adult rats. *Andrologia.* 2018:e13047. doi: 10.1111/and.13047.
- Soltani M, Moghimian M, Eivari SHA, Shoorei H, Khaki A, Shokoohi M. Protective effects of *Matricaria chamomilla* extract on torsion/detorsion-Induced tissue damage and oxidative stress in adult rat testis. *Int J Fertil Steril.* 2018;12(3):242-248. doi: 10.22074/ijfs.2018.5324.
- Soltani M, Moghimian M, Abtahi H, Shokoohi M. The protective effect of *Matricaria chamomilla* extract on histological damage and oxidative stress induced by Torsion/Detorsion in adult rat ovary. *Int J Womens Health Reprod Sci.* 2017;5(3):187-92. doi:10.15296/ijwhr.2017.34
- Shojaee SS, Vahdati A, Assaei R, Sepehrimanesh M. Effect of *Galega officinalis* leaf powder and *Trigonella foenum-graecum* seed powder on blood glucose levels and weight gain in a diabetes mellitus rat model. *Comp Clin Path.* 2015;24(1):145-8. doi:10.1007/s00580-013-1873-7
- Abtahi-Eivari SH, Moghimian M, Soltani M, et al. The effect of *Galega officinalis* on hormonal and metabolic profile in a rat model of polycystic ovary syndrome. *Int J Womens Health Reprod Sci.* 2018;6(3):276-82. doi:10.15296/ijwhr.2018.46
- Rasekh HR, Nazari P, Kamli-Nejad M, Hosseinzadeh L. Acute and subchronic oral toxicity of *Galega officinalis* in rats. *J Ethnopharmacol.* 2008;116(1):21-6.
- Abtahi-Evari S-H, Shokoohi M, Abbasi A, Rajabzade A, Shoorei H, Kalarestaghi H. Protective effect of *Galega officinalis* extract on Streptozotocin-induced kidney damage and biochemical factor in diabetic rats. *Crescent Journal of Medical and Biological Sciences.* 2017;4:108-14.
- Oubre A, Carlson T, King S, Reaven G. From plant to patient: an ethnomedical approach to the identification of new drugs for the treatment of NIDDM. *Diabetologia.* 1997;40(5):614-7.
- Kahkeshani N, Hadjiakhoondi A, Maafi N, Khanavi M. Standardization of a galactagogue herbal mixture based on its total phenol and flavonol contents and antioxidant activity. *Research Journal of Pharmacognosy.* 2015;2(1):35-9.
- Shoorei H, Khaki A, Khaki AA, Hemmati AA, Moghimian M, Shokoohi M. The ameliorative effect of carvacrol on oxidative stress and germ cell apoptosis in testicular tissue of adult diabetic rats. *Biomed Pharmacother.* 2018 Dec 28;111:568-578. doi: 10.1016/j.biopha.2018.12.054.
- Agarwal A, Gupta S, Sharma RK. Role of oxidative stress in female reproduction. *Reprod Biol Endocrinol.* 2005;3(1):28.
- Agarwal A, Aponte-Mellado A, Premkumar BJ, Shaman A, Gupta S. The effects of oxidative stress on female reproduction: a review. *Reprod Biol Endocrinol.* 2012;10(1):49.
- Shoorei H, Khaki A, Ainehchi N, et al. Effects of *Matricaria chamomilla* Extract on Growth and Maturation of Isolated Mouse Ovarian Follicles in a Three-dimensional Culture System. *Chinese Medical Journal.* 2018;131(2):218.
- Kumtepe Y, Odabasoglu F, Karaca M, et al. Protective effects of telmisartan on ischemia/reperfusion injury of rat ovary: biochemical and histopathologic evaluation. *Fertil Steril.* 2010;93(4):1299-307. doi: 10.1016/j.fertnstert.2008.12.016.
- Mostajeran F, Naderi M, Adibi S. Effects of melatonin on histopathological changes after experimental ovarian torsion-detorsion in cat. *Iran J Reprod Med.* 2007;5(4):177.
- Yuk JS, Kim LY, Shin JY, Choi DY, Kim TY, Lee JH. A national population-based study of the incidence of adnexal torsion in the Republic of Korea. *Int J Gynaecol Obstet.* 2015;129(2):169-70. doi: 10.1016/j.ijgo.2014.11.027.
- Majdi Seghinsara A, Hassanzadeh Taheri MM, Khaki A, et al. Panax ginseng extract improves follicular development after mouse preantral follicle 3D culture. *Cell Journal (Yakhteh).* 2019;21(2). doi:10.22074/cellj.2019.5733
- Túnez I, Feijóo M, Collado JA, et al. Effect of testosterone on oxidative stress and cell damage induced by 3-nitropropionic acid in striatum of ovariectomized rats. *Life Sci.* 2007;80(13):1221-7.
- Celik O, Turkoz Y, Hascalik S, et al. The protective effect of caffeic acid phenethyl ester on ischemia-reperfusion injury in rat ovary. *European Journal of Obstetrics & Gynecology and Reproductive Biology.* 2004;117(2):183-8.

© 2019 The Author (s); This is an open-access article distributed under the terms of the Creative Commons Attribution License (<http://creativecommons.org/licenses/by/4.0>), which permits unrestricted use, distribution, and reproduction in any medium, provided the original work is properly cited.