




Available online at  
**ScienceDirect**  
 www.sciencedirect.com

Elsevier Masson France  
**EM|consulte**  
 www.em-consulte.com



## LETTER TO THE EDITOR

### Drug-induced hepatitis (DIH) after SARS-CoV-2 vaccination



#### 1. Introduction

The 2019 coronavirus disease (COVID-19) caused by severe acute respiratory syndrome coronavirus 2 (SARS-CoV-2) has emerged as a major worldwide burden, resulting in serious public health challenges and claiming millions of infected cases and deaths [1]. This called for an urgent need for vaccinations against COVID-19. Several vaccines using diverse platforms were developed. The BBIBP-CorV vaccine (also known as the Sinopharm COVID-19 vaccine) is one of these vaccines, which is an inactivated vaccine and has been widely administered in the Middle East and Iran since December 2020. In its clinical trials, the predominant side effects were injection site pain, fatigue, and headache with mainly mild to moderate intensity. However, few cases have been reported with more severe side effects that required hospitalization [2].

As vaccination moves further, its side effects, which have not been fully explored start to appear. Recently, one of these side effects that has been frequently reported is liver injury. So far, COVID-19 vaccination has been associated with the development of various liver disorders, such as autoimmune hepatitis (AIH), primary biliary cholangitis (PBC), and primary sclerosing cholangitis (PSC), presumably through cross-reactivity with host cells [3–5]. Additionally, several studies have reported cases of DIH following Pfizer-BioNTech [6] and Sinopharm [7] SARS-CoV-2 vaccination. Herein, we reported another case of DIH following

Sinopharm COVID-19 vaccination in a 34-year-old female patient.

A 34-year-old female patient was presented to our outpatient gastrointestinal clinic with a one-week history of abdominal pain that began one week after receiving the first dose of the Sinopharm SARS-CoV-2 vaccine on 14<sup>th</sup> September 2021 (Fig. 1). The pain was described as a non-radiating constant dull ache with intermittent sharp pains in the right upper quadrant of the abdomen, which was not accompanied by nausea, vomiting, diarrhea, fever, shortness of breath, and chest pain. Past medical history of the patient was significant for cholecystectomy [2019]. Liver enzymes were completely normal in a routine check-up two years prior. She was not taking any medications or herbal remedies and did not consume alcohol. There was no recent complaint of SARS-CoV-2 infection symptoms, and she denied a history of previous COVID-19 infection or contact with a known COVID-19 infected individual.

On examination, the patient's mental status was intact and vital signs were stable. She had obvious scleral icterus and jaundice. Abdominal examination was notable for tenderness in the right upper quadrant without guarding or rigidity. Liver span was normal, and no sign of splenomegaly, hepatomegaly, or lymphadenopathy was identified.

Laboratory investigations were significant for hepatic function panel with elevated levels of total bilirubin 5.41 mg/dL (normal < 1.2 mg/dL), direct bilirubin 2.14 mg/dl (normal < 0.3 mg/dl), indirect bilirubin 3.27 mg/dl (normal < 1.1 mg/dl), aspartate aminotransferase (AST) 688 U/L (normal < 31 U/L), alanine aminotransferase (ALT) 983 U/L (normal < 31 U/L), alkaline phosphatase (ALP) 549 U/L (normal range: 64–320 U/L) (Fig. 2). The laboratory results for hepatitis panel, including, reactive IgG and IgM antibodies for hepatitis A, B, C, and E virus, cytomegalovirus, Epstein-Barr virus, and herpes virus were reported negative.

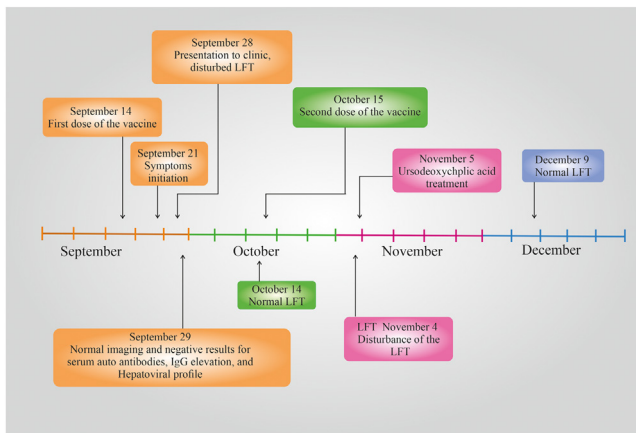
The hematological panel was normal. Serum immunoglobulins G (IgG) and ceruloplasmin were within normal ranges. Serological autoimmune studies (anti-nuclear antibody (ANA), anti-smooth muscle antibody (SMA), and anti-liver kidney microsome type 1 antibody (LKM-1 Ab)) were negative. The urine analysis was normal.

The patient underwent abdominal ultrasound, abdominal computerized tomography (CT) scan, and magnetic resonance cholangiopancreatography (MRCP), which showed normal liver parenchyma, normal portal vein flow, no

*Abbreviations:* ALP, alkaline phosphatase; ALT, alanine aminotransferase; AMA, anti-mitochondrial antibody; ANA, anti-nuclear antibodies; APCA, anti-parietal cell antibody; ASA, acetylsalicylic acid; ASMA, anti-smooth muscle antibodies; AST, aspartate aminotransferase; COVID-19, coronavirus disease 2019; CT, computerized tomography; DIH, drug-induced hepatitis; ds-DNA, double-stranded DNA antibodies; GGT, gamma-glutamyl transferase; HAV Ab, hepatitis A virus antibody; IgG, immunoglobulins G; LC, liver cytosol; LKM-1 Ab, liver-kidney microsome type 1 antibody; MRCP, magnetic resonance cholangiopancreatography; PBC, primary biliary cholangitis; PSC, primary sclerosing cholangitis; SARS-CoV-2, severe acute respiratory syndrome coronavirus 2; SLA, soluble liver antigen.

<https://doi.org/10.1016/j.clinre.2022.102028>

2210-7401/© 2022 Published by Elsevier Masson SAS.



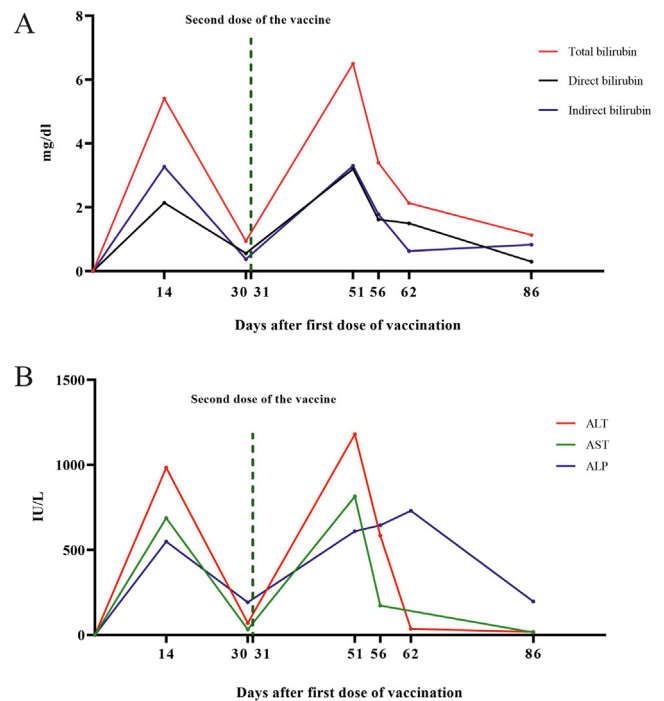
**Fig. 1** Timeline of the patients' clinical and para-clinical status.

ascites, and no evidence of biliary lithiasis or dilatation of biliary ducts. The gallbladder was not seen, which was in line with the patients' history of cholecystectomy. Additionally, there were no significant abnormalities of kidneys, spleen, pancreas, and abdominal vessels in the imaging.

Jaundice and other symptoms lasted for one week and then decreased in intensity. One day before administration of the second dose of Sinopharm COVID-19 vaccine, on 14<sup>th</sup> October 2021, liver tests were within normal ranges, except for ALT (70 U/L). However, one week after the second dose, the same clinical presentations reappeared. Two weeks later, laboratory findings were: total bilirubin 6.5 mg/dl, direct bilirubin 3.2 mg/dl, indirect bilirubin 3.3 mg/dl, AST 815 U/L, ALT 1180 U/L, ALP 610 U/L, with normal hematological panel (Fig. 2). Hepatitis panel, serological tests for autoimmune liver disease, and abdomen imaging did not repeat. Additionally, the Roussel Uclaf Causality Assessment Method (RUCAM), an established tool to quantitatively evaluate causality in cases of suspected drug/herb induced liver injury [8], score for the patient was 8, showing a probable relationship between vaccination and liver damage. Since all work-up excluded infection, autoimmune, or obstruction liver diseases, and along with the high score of the RUCAM, she was diagnosed with SARS-CoV-2 vaccine developed DIH. Oral capsule of Ursodeoxycholic (300 mg) was administered empirically based on decision of the infectious disease specialist. Corticosteroid treatment was not used since there was no evidence for the incidence of autoimmunity. The patient's liver function values were completely normalized within 35 days after treatment (Fig. 1).

## 2. Discussion

This study presented a 34-year-old female patient with hepatitis after receiving both the first and second dose of the COVID-19 vaccine. Several cases of hepatitis have been reported after COVID-19 vaccines, but most of them were diagnosed as vaccine-triggered AIH. Although DIH cases following COVID-19 vaccination have also been reported before, to our best knowledge, the present study is the first report of the DIH occurrence following both the first and



**Fig. 2** Trends of the total, direct, and indirect bilirubin levels (mg/dl) (A) and liver enzymes levels (U/L) (B) during the two episodes of liver injury after two dose of the COVID-19 vaccinations. ALP; alkaline phosphatase, AST; aspartate aminotransferase, ALT; alanine aminotransferase.

second dose of the Sinopharm COVID-19 vaccine and only second to [7] to report hepatitis following administration of this vaccine.

By ruling out the other causes of hepatitis, such as infectious, autoimmune, or obstructive hepatitis, the close relationship between the timeline of the vaccination and symptoms onset may be interpreted as the contribution of the Sinopharm COVID-19 vaccination in the development of DIH in our patient. As causality cannot be proven, it is possible that this association is just coincidental. However, as the viral spike protein appears to be responsible for damaging tissues like the liver [9], it is plausible that inactivated COVID-19 vaccines, like Sinopharm, may also trigger liver injuries in vaccinated individuals. Therefore, it is crucial to note the DIH rather than AIH as one of the side effects of the Sinopharm COVID-19 vaccine to avoid prescribing immunosuppressive drugs like corticosteroids.

## 3. Conclusion

Vaccine-induced hepatitis is a rare complication, and the majority of reported cases have been minor and self-limited. In the background of benefits over risks from the vaccine, it is essential that this article should not discourage the general population from taking the vaccine. However, it is crucial to inform the healthcare providers about the potential association between the vaccine and the onset of liver injuries as more and more countries start to consider the first and second booster dose of the COVID-19 vaccination. Further clinical and epidemiological studies are needed to

confirm the causality between COVID-19 vaccination and the development of liver injuries like DIH.

### Patient consent statement

Written informed consent was obtained from the patient for publication of this case report.

### Ethical approval

This study was approved by the ethics committee of Ardabil University of Medical Sciences.

### Funding

None.

### Contributions

Sh. Habibzadeh and E. Safarzadeh were involved in conceptualization, preparing the original draft, supervision, and Validation. E. Safarzadeh, and A. Asgarzadeh involved in Methodology and data collection. A. Asgarzadeh and V. Asghariazar involved in writing the manuscript. V. Asghariazar work out on software. All authors involved in review & editing of the manuscript.

### Declaration of Competing Interest

The authors have no conflicts of interest to declare that are relevant to the content of this article.

### Acknowledgments

The authors would like to thank the staff of Imam Khomeini hospital for providing great support.

### References

- [1] Guan W-J, et al. Clinical characteristics of 2019 novel coronavirus infection in China. *MedRxiv* 2020.
- [2] Saeed BQ, et al. Side effects and perceptions following Sinopharm COVID-19 vaccination. *Int J Infect Dis* 2021;111:219-26.
- [3] Bartoli A, et al. Primary biliary cholangitis associated with SARS-CoV2 infection. *J Hepatol* 2021.
- [4] Caso F, et al. Could Sars-coronavirus-2 trigger autoimmune and/or autoinflammatory mechanisms in genetically predisposed subjects? *Autoimmun Rev* 2020;19(5):102524.
- [5] Bril F. Autoimmune hepatitis developing after coronavirus disease 2019 (COVID-19) vaccine: one or even several swallows do not make a summer. *J Hepatol* 2021.
- [6] Mann R, Sekhon S, Sekhon S. Drug-induced liver injury after COVID-19 vaccine. *Cureus* 2021;13(7).
- [7] Ghorbani H, et al. Drug-induced hepatitis after Sinopharm COVID-19 vaccination: a case study of a 62-year-old patient. *Int J Surg Case Rep* 2022:106926.
- [8] Danan G, Teschke R. RUCAM in drug and herb induced liver injury: the update. *Int J Mol Sci* 2016;17(1):14.
- [9] Wang Y, et al. SARS-CoV-2 infection of the liver directly contributes to hepatic impairment in patients with COVID-19. *J Hepatol* 2020;73(4):807-16.

Ali Asgarzadeh<sup>a</sup>, Shahram Habibzadeh<sup>b,\*</sup>, Vahid Asghariazar<sup>c,d</sup>, Elham Safarzadeh<sup>e,\*</sup>

<sup>a</sup> Students Research Committee, School of Medicine, Ardabil University of Medical Sciences, Ardabil, Iran

<sup>b</sup> Department of Internal Medicine, Emam Khomeini Hospital, Ardabil University of Medical Sciences, Ardabil, Iran

<sup>c</sup> Deputy of Research and Technology, Ardabil University of Medical Sciences, Ardabil, Iran

<sup>d</sup> Immunology Research Center, Ardabil University of Medical Sciences, Ardabil, Iran

<sup>e</sup> Department of Microbiology, Parasitology, and Immunology, Ardabil University of Medical Sciences, Ardabil, Iran

\* Corresponding author.

E-mail address: [E.safarzadeh@arums.ac.ir](mailto:E.safarzadeh@arums.ac.ir) (E. Safarzadeh).

Received 19 July 2022; Received in revised form 17 September 2022; Accepted 30 September 2022

Available online 3 October 2022