

A case of Hermansky-Pudlak with dyspnea

Ali Hossein Samadi Takaldani ¹, Nima Javanshir ^{2,*}, Maryam Salimi ³ and Mohammad Negaresh ³

¹Department of Internal Medicine (Pulmonology Division), School of Medicine, Ardabil University of Medical Sciences, Ardabil, Iran

²Faculty of Medicine, School of Medicine, Ardabil University of Medical Sciences, Ardabil, Iran

³Department of Internal Medicine, School of Medicine, Ardabil University of Medical Sciences, Ardabil, Iran

*Correspondence address. Students Research Committee, Faculty of Medicine, Ardabil University of Medical Sciences, Ardabil, Iran. Tel: +984533534818;

Fax: +984533534817; E-mail: Nimajvn95@gmail.com

Abstract

Hermansky-Pudlak syndrome (HPS) is a rare multisystem disorder inherited in an autosomal recessive manner. Its prevalence is 1 in 500 000 to 1 000 000 people worldwide. The cause of this disorder is genetic mutations that lead to defective organelles of lysosomes. In this report, a 49-year-old man is introduced who was referred to the medical center with ocular albinism and recently exacerbated shortness of breath. Imaging showed peripheral reticular opacities, ground-glass opacities of the lungs with subpleural sparing in some regions, and thickening of bronchovascular bundles, which were all in favor of non-specific interstitial pneumonia. This imaging pattern is an unusual finding in a patient with HPS.

INTRODUCTION

Hermansky-Pudlak syndrome (HPS) is a rare multisystem disorder inherited and transmitted in an autosomal recessive manner [1]. Its prevalence is 1 in 500 000 to 1 000 000 people worldwide [2]. The cause of this disorder is genetic mutations that lead to defective lysosome-related organelles (LROs). Among these organelles are melanosomes, which synthesize and store melanin, and dense platelet granules, which store small signaling molecules involved in platelet aggregation [3, 4]. Due to these processes, patients with HPS often suffer from oculocutaneous albinism (OCA), which leads to hypopigmentation of hair, skin and eyes as well as iris transilluminations, visual acuity, congenital nystagmus, foveal hypoplasia and increased optic nerve decussation [5]. Other symptoms include bleeding diathesis, immunodeficiency, granulomatous colitis and pulmonary fibrosis. People with bleeding diathesis may experience bruising, bleeding gums, lower gastrointestinal bleeding and epistaxis [6].

In this report, we present the case of a 49-year-old patient who was referred to the medical center with the chief complaint of exacerbated shortness of breath in the past 6 months, along with other symptoms such as dry cough, photophobia, photosensitivity, nystagmus and epistaxis.

CASE PRESENTATION

The patient was a 49-year-old man admitted to the hospital with shortness of breath and a dry cough. Although his shortness of breath started 5 years ago and emerged when walking up steep hills or hurrying (MMRC I), he did not visit a doctor. However, in the last 6 months, he has experienced an exacerbation of symptoms during activities and at rest (MMRC III-IV), accompanied by a dry cough. He also complained of other symptoms, including

photophobia, photosensitivity and epistaxis. However, he did not mention any history of fever, sweating, weight loss, diarrhea or abdominal pain. In appearance, he had white hair and pale white skin. The same symptoms were evident in his sister and his maternal family.

Generalized skin hypopigmentation and silvery white hair were observed in the physical examination. The eyes were blue-green. Nystagmus in the eyes was horizontal, and exotropia with a high angle was also evident. Examination of the fundus showed hypopigmentation and hypoplasia of the fovea. Clubbing could be seen in the fingers (Figure 1). Fine crackles were heard in the bases of both lungs on auscultation.

His blood pressure was 120/70 mmHg, pulse rate was 88 beats/min, respiratory rate was 20 breaths/min and oxygen saturation level was 89% on room air at rest.

Due to the patient's epistaxis, a blood test was requested, the results of which are presented in Table 1.

A chest X-ray was performed for the patient, and no significant findings were obtained. Due to the long duration and persistence of the symptoms, a computed tomography (CT) scan of the lungs with contrast was requested for the patient. The results showed peripheral reticular opacities and ground-glass opacities of the lungs with subpleural sparing in some regions, along with the thickening of bronchovascular bundles. Also, evidence of subpleural fibrosis was reported (Figure 2). A pulmonary function test (PFT) was requested for the patient, the results of which showed no particular finding.

DISCUSSION

HPS was first reported in 1959 by Hermansky and Pudlak. In their investigations, they identified two cases that manifested similar symptoms of albinism, hemorrhagic diathesis, unusual

Received: October 27, 2022. Revised: December 16, 2022. Accepted: December 29, 2022

© The Author(s) 2023. Published by Oxford University Press. All rights reserved. For Permissions, please email: journals.permissions@oup.com

This is an Open Access article distributed under the terms of the Creative Commons Attribution Non-Commercial License (<https://creativecommons.org/licenses/by-nc/4.0/>), which permits non-commercial re-use, distribution, and reproduction in any medium, provided the original work is properly cited. For commercial re-use, please contact journals.permissions@oup.com

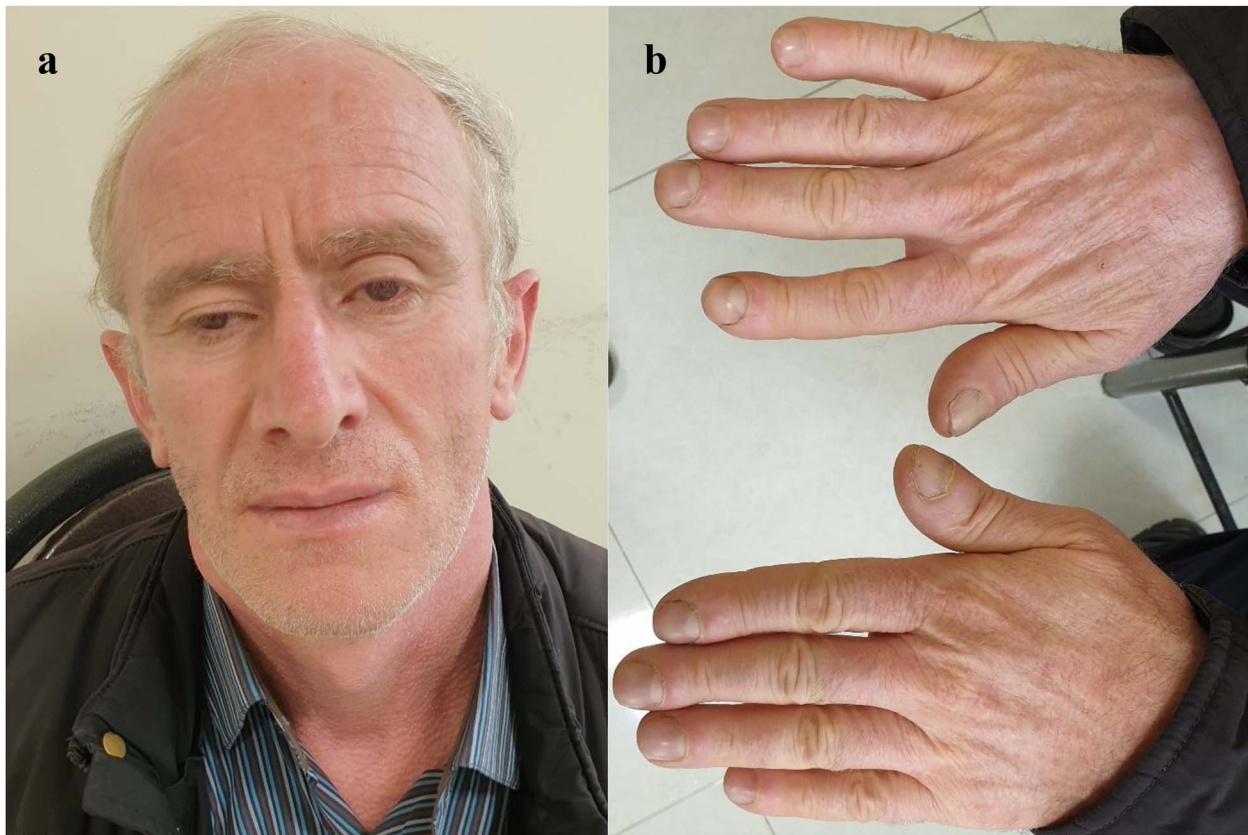

Figure 1. Patient's pale white skin, white hair, blue-green eyes (a), and clubbing of fingers (b).

Table 1. The patient's lab results

	Reference value	Admission
WBC (cu/mm)	4000–10 000	10 020
Hb (g/dl)	12–16	16.7
MCV (fL)	80–100	92.1
Platelets (10^6 /ml)	150–450	278
PTT (s)	30–35	35
INR (Index)	1–1.4	1.2
Creatinine (mg/dl)	0.5–1.4	1.0
ESR (mm/h)	<20	21
LDH (IU/L)	0–500	535
CRP	Negative	Negative
PCR Covid19	Negative	Negative

pigmented reticular cells in their bone marrow and lung disease. They chose the name of HPS for this set of symptoms. The presence of ocular albinism and proof of lack of a platelet storage tank confirms the diagnosis of this disease. Albinism with varying degrees of hypopigmentation can be identified in patients with HPS shortly after birth, but other symptoms need time to be detectable; for example, excessive bleeding or bruising is usually not detected until circumcision or starting to walk.

The 'gold standard' test for the platelet abnormality in HPS is an analysis by whole-mount electron microscopy for the absence of dense bodies. Genetic testing is required to diagnose the type of disease and determine the prognosis of the disease, but currently, it is used less often due to the high cost. Hence, in the absence of genetic confirmation, patients with the classic manifestations of this syndrome, such as albinism with bleeding disorders, colitis

or pulmonary fibrosis, are considered to have HPS unless proven otherwise [7].

Hair color in HPS patients varies from white to brown, which can darken with age. Skin color can be white or olive [6]. Also, congenital nystagmus (CN) is seen in almost all children with HPS and most adults [8].

The HPS platelet storage pool deficiency causes bleeding diathesis, often manifests in infancy, and persists throughout life. Usually, bleeding starts with a simple blow or scratch on the skin's surface [9]. Also, epistaxis is one of the symptoms that is more common in childhood and decreases with age [6].

Colitis in these patients is a type of granulomatous inflammation of the colon, which is clinically and pathologically similar to Crohn's disease [10]. Furthermore, it becomes severe in 15% of the cases and requires surgery. However, in milder cases, it is partially improved by treatments similar to Crohn's disease, such as anti-inflammatory drugs, immunosuppressants and infliximab [9, 11, 12].

Immunodeficiency is often seen in patients with HPS-2 but not in HPS-1 and HPS-4 patients. New studies have shown that dysfunction of cytotoxic T cells, dendritic cells and natural killer (NK) cells lead to immunodeficiency in these patients; nevertheless, the mechanisms that lead to a defective immune system in patients with HPS-2 have remained unknown [13, 14].

Pulmonary fibrosis following HPS (HPS-PF) is the most serious complication and the primary cause of death among patients with HPS. In HPS-1, HPS-2 and HPS-4 subtypes, HPS-PF occurs in the fourth and sixth trimesters of life and is diagnosed by the development of dyspnea and increasingly severe hypoxemia [15]. It is similar to idiopathic pulmonary fibrosis (IPF) in clinical

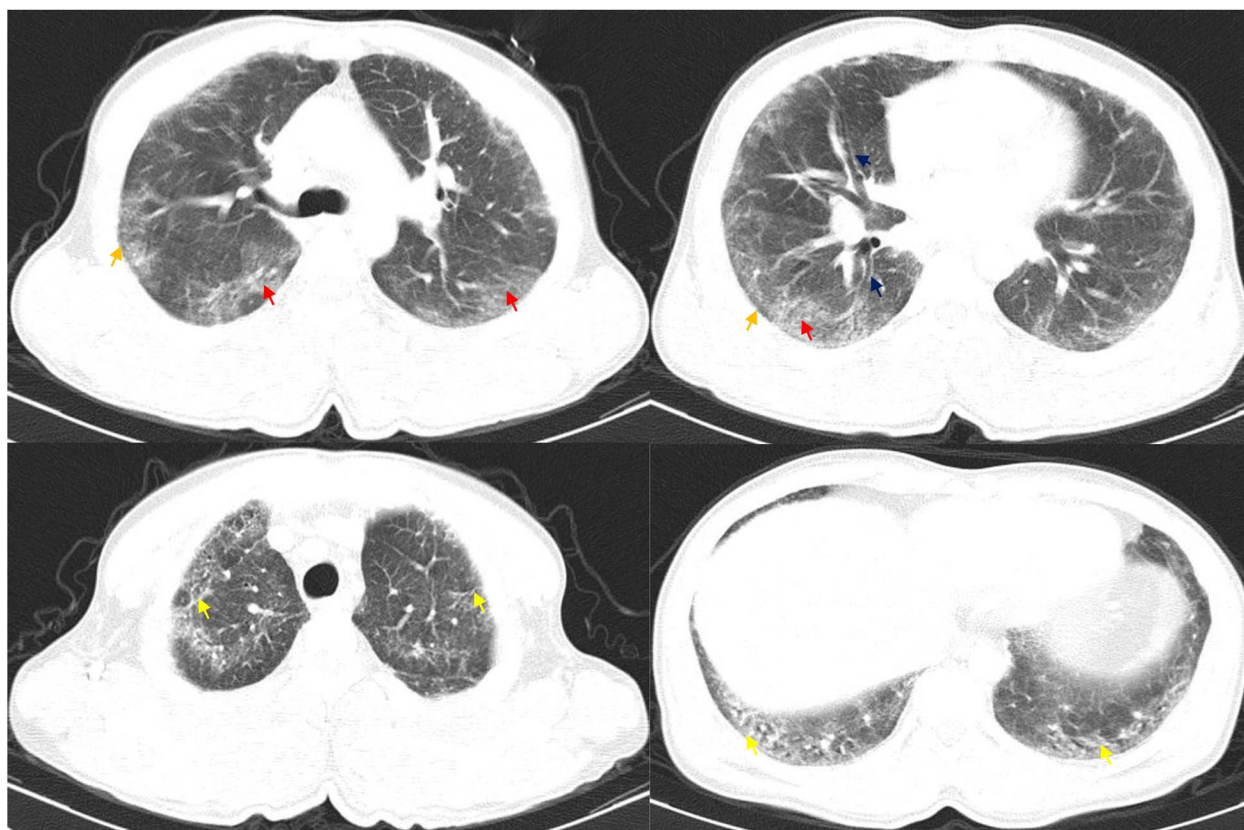


Figure 2. The patient's CT scan shows reticular patterns (yellow arrow), ground-glass opacities (red arrow), subpleural sparing (orange arrow) and bronchoalveolar bundles thickening (blue arrow). Findings are suggestive of the possible diagnosis of fibrotic NSIP.

and imaging terms [7]. Like IPF, it leads the patients to a stage of progressive and irreversible lung tissue scarring, ultimately resulting in respiratory failure and death within approximately 10 years after the onset of symptoms [16]. While many cellular and molecular processes have been identified as essential factors in developing HPS-PF, little information is available on its mechanisms and cellular pathways. Hence, no therapies have been developed to target these cellular and molecular pathways [17]. Currently, there is no therapeutic intervention for the treatment of HPS-PF. The primary basis of treatment is lung transplantation, which faces the problems of finding a donor and the following surgical complications, and is not suitable for all patients [7].

High-resolution chest CT (HRCT) is used to diagnose and follow up on pulmonary fibrosis. Radiographic findings are mostly observed in the periphery of the lung, and as the disease progresses, it moves toward the central part of the lung. Some HRCT findings include ground glass opacities and reticulation of interstitial spaces in the early stages and loss of lung volume, honeycombing, and traction bronchiectasis in the advanced stages of the disease. The predominant pattern in HPS-PF is usual interstitial pneumonia (UIP) type [7]. Regardless, based on the evidence available from our patient, in addition to the UIP pattern, the nonspecific interstitial pneumonia (NSIP) pattern is also clearly visible. However, its definitive diagnosis is by lung biopsy, which was not performed due to the patient's history of epistaxis and bleeding diathesis.

The patient presented in this report, as well as his family members, had symptoms of HPS. Therefore, he was referred for aggravated dyspnea. The imaging findings were suggestive of an NSIP pattern that is unusual for HPS.

ACKNOWLEDGMENTS

Not applicable.

CONFLICT OF INTEREST

The authors declare that they have no competing interest to disclose.

FUNDING

This article was prepared without any support or funding.

ETHICAL APPROVAL

Not applicable.

CONSENT

Written informed consent was obtained from the patient to publish this case report and any accompanying images. A copy of the written consent is available for review by the Editor-in-Chief of this journal.

GUARANTOR

The corresponding author Nima Javanshir is nominated as the guarantor of the paper.

DATA AVAILABILITY STATEMENT

The datasets used and/or analyzed during the current study are available from the corresponding author upon reasonable request.

REFERENCES

1. Witkop CJ, Almadovar C, Pineiro B, Babcock MN. Hermansky-Pudlak syndrome (HPS): an epidemiologic study. *Ophthalmic Paediatr Genet* 1990;**11**:245–50.
2. Rojas WDJ, Young LR. Hermansky–Pudlak syndrome. In: *Seminars in Respiratory and Critical Care Medicine*. Thieme Medical Publishers, 2020.
3. Hermansky F, Pudlak P. Albinism associated with hemorrhagic diathesis and unusual pigmented reticular cells in the bone marrow: report of two cases with histochemical studies. *Blood* 1959;**14**:162–9.
4. Seiji M, Fitzpatrick TB, Simpson R, Birbeck M. Chemical composition and terminology of specialized organelles (melanosomes and melanin granules) in mammalian melanocytes. *Nature* 1963;**197**:1082–4.
5. Gahl WA, Brantly M, Kaiser-Kupfer MI, Iwata F, Hazelwood S, Shotelersuk V, et al. Genetic defects and clinical characteristics of patients with a form of oculocutaneous albinism (Hermansky–Pudlak syndrome). *N Engl J Med* 1998;**338**:1258–65.
6. Gahl WA, Brantly M, Kaiser-Kupfer MI, Iwata F, Hazelwood S, Shotelersuk V, Duffy LF, Kuehl EM, Troendle J, Bernardini I. Genetic defects and clinical characteristics of patients with a form of oculocutaneous albinism (Hermansky–Pudlak syndrome). *N Engl J Med* 1998;**338**:1258–65.
7. Vicary GW, Vergne Y, Santiago-Cornier A, Young LR, Roman J. Pulmonary fibrosis in Hermansky–Pudlak syndrome. *Ann Am Thorac Soc* 2016;**13**:1839–46.
8. Gradstein L, FitzGibbon EJ, Tsilou ET, Rubin BI, Huizing M, Gahl WA. Eye movement abnormalities in hermansky-pudlak syndrome. *J Am Assoc Pediatr Ophthalmol Strabismus* 2005;**9**:369–78.
9. Seward SL, Gahl WA. Hermansky-Pudlak syndrome: health care throughout life. *Pediatrics* 2013;**132**:153–60.
10. Salvaggio HL, Graeber KE, Clarke LE, Schlosser BJ, Orlov SJ, Clarke JT. Mucocutaneous granulomatous disease in a patient with Hermansky-Pudlak syndrome. *JAMA Dermatol* 2014;**150**:1083–7.
11. El-Chemaly S, Young LR. Hermansky-Pudlak syndrome. *Clin Chest Med* 2016;**37**:505–11.
12. Hazzan D, Seward S, Stock H, Zisman S, Gabriel K, Harpaz N, et al. Crohn's-like colitis, enterocolitis and perianal disease in Hermansky–Pudlak syndrome. *Color Dis* 2006;**8**:539–43.
13. Gil-Krzewska A, Murakami Y, Peruzzi G, O'Brien KJ, Merideth MA, Cullinane AR, et al. Natural killer cell activity and dysfunction in Hermansky-Pudlak syndrome. *Br J Haematol* 2017;**176**:118–23.
14. Sasai M, Linehan MM, Iwasaki A. Bifurcation of toll-like receptor 9 signaling by adaptor protein 3. *Science* 2010;**329**:1530–4.
15. Bachli EB, Brack T, Eppler E, Stallmach T, Trüeb RM, Huizing M, et al. Hermansky–Pudlak syndrome type 4 in a patient from Sri Lanka with pulmonary fibrosis. *Am J Med Genet A* 2004;**127**:201–7.
16. Gahl WA, Brantly M, Troendle J, Avila NA, Padua A, Montalvo C, et al. Effect of pirfenidone on the pulmonary fibrosis of Hermansky–Pudlak syndrome. *Mol Genet Metab* 2002;**76**:234–42.
17. Velázquez-Díaz P, Nakajima E, Sorkhdini P, Hernandez-Gutierrez A, Eberle A, Yang D, et al. Hermansky-Pudlak syndrome and lung disease: pathogenesis and therapeutics. *Front Pharmacol* 2021;**12**:644671.