

# The Incidence of Berry Aneurysm in the Iranian Population: An Autopsy Study

## Otopsi Çalışması: İnan Toplumunda Berry Anevrizması Görülme Sıklığı

### ABSTRACT

Intracranial berry aneurysms are the most common kind of aneurysms in the brain, and are caused by head trauma in 1% of cases. They may remain asymptomatic for a long time or may rupture and cause intracranial hemorrhage. These aneurysms are associated with a high mortality rate. A definitive diagnosis can be made by angiography or autopsy. We studied the cadavers of 425 people who passed away accidentally. The number and location of berry aneurysms were recorded. Twelve cases (2.82%) were found to have a single berry aneurysm and two (0.47%) had multiple aneurysms. The aneurysms had a tendency to occur in the frontal half of the Circle of Willis and in approximation of the bifurcation of arteries.

The main characteristics of cases of berry aneurysm in the Iranian population were in agreement with that reported in previous Western studies.

**KEY WORDS:** Berry aneurysms, Autopsy study, Epidemiology, Iran

### ÖZ

Berry anevrizmaları kafa içinde en sık görülen anevrizma tipidir ve yaklaşık yüzde biri travma sonrası meydana gelir. Bu anevrizmalar uzun süre asemptomatik kalabilir veya patlayarak kafa içi kanamaya yol açabilir. Bu anevrizmalar yüksek mortalite riski taşımaktadır. Kesin tanı anjiyografi ile ya da; postmortem otopsi ile konabilir. Bu çalışmada 425 kadavrada inceleme yapılmış ve Berry anevrizmalarının yeri ve sayısı tesbit edilmiştir. Toplam 12 vakada (% 2.8) tekli, 2 vakada (% 0.47) birden fazla anevrizma bulundu. Anevrizmaların yarısı Willis poligonunun ön yarısında ve arter bifurkasyonlarında bulundu. Yapılan çalışmada İnan toplumunda görülen Berry anevrizmalarının batı toplumu için yapılan çalışmalarla uyum içinde olduğu gösterilmiştir.

**ANAHTAR SÖZCÜKLER:** Berry anevrizmaları, Otopsi, Epidemiyoloji, İnan

Babak MOSTAFAZADEH<sup>1</sup>  
Esmail FARZANEH SHEIKH<sup>2</sup>  
Tahmineh AFSHARIAN  
SHISHVAN<sup>3</sup>  
Farnaz Nasl SERAJI<sup>4</sup>  
Hojjat SALMASIAN<sup>5</sup>

- 1 Shahid Behashti University of Medical Sciences, Tehran, Iran
- 2 Ardabil University of Medical Sciences, Ardabil, Iran
- 3 Uromiyeh Health Center, Uromiyeh, Iran
- 4 Azad University Ardabil branch, Ardabil, Iran
- 5 Medical Sciences/ University of Tehran, Tehran, Iran

Received : 25.12.2008

Accepted : 10.06.2008

Correspondence address:

**Babak MOSTAFAZADEH**

P.O. Box: 13185-1678, Tehran, Iran

Phone : +9821 66439463

Fax : +9821 66919206

E-mail : swt\_f@yahoo.com

## INTRODUCTION

An intracranial berry aneurysm, also known as a saccular aneurysm, is a sac-like out-pouching in a cerebral blood vessel, which can seem berry-shaped, hence the name. Such aneurysms usually reside on the Circle of Willis, where main cerebral arteries bifurcate and link together. They are often located at or near the bifurcation of arteries (5).

Intracranial berry aneurysms are the most common kind of aneurysms in the brain. According to earlier radiographic and autopsy studies, their incidence is 5 percent or 10 to 15 million people in the United States (13). Newer studies estimate the incidence of cerebral aneurysms to be 0.2% to 8.9% in the general population (16). Although berry aneurysms are likely to rupture and cause complications including stroke and vasospasm, most aneurysms never rupture, particularly if they are small (4). Aneurysmal subarachnoid hemorrhage (SAH) occurs in 6 to 16 per 100,000 people (11). This yields to 27,000 new cases of SAH in United States each year (10). Once ruptured, it can be accompanied with a mortality rate of up to 65% (1).

The pathogenesis of saccular aneurysm formation is multifactorial (19). The risk factors for developing berry aneurysms include any condition that causes hypertension (including atherosclerosis, renal disease and vasculitis) or weakening of blood vessel walls (such as connective tissue disorders, infections and head trauma) (2,8,15)

Head trauma is a rare etiology for intracranial aneurysms. It is estimated that only 1% of intracranial aneurysms are due to head trauma (6). They are classified as true, false and mixed aneurysms with false aneurysms being the most common. They are thought to result from either direct osseous injury or stretching or compression of an artery against the tentorium or falx, and usually present with delayed intracranial hemorrhage initiating in about 21 days after the head trauma. The outcome varies broadly from spontaneous resolution to prompt death due to rupture, and the mortality rate may be as high as 50% (6,7,12). They may occur even after mild blunt injuries and happen more in children than in adults. They have also been reported in infancy (9, 14).

In this study, we aimed to evaluate the anatomical characteristics of berry aneurysms in the Iranian population.

## MATERIALS and METHODS

This cross-sectional study extended from April 2005 to March 2007 and was performed on cadavers referred to the Tehran Legal Medicine Center. Cases were selected by random sampling from the cadavers with an age of 10 years or more at the time of death if the death was reported as accidental, and macroscopic cerebral hemorrhage was not observed. Restriction of the sample to subjects who passed away by accidental causes would ensure that other morbidities that might be in association with a higher risk of berry aneurysm in their subpopulation would not complicate our results. Exclusion of cases with cerebral hemorrhage would eliminate cases with other types of cerebral aneurysms (dissecting, fusiform, etc) which are typically associated with head trauma.

We studied the Circle of Willis in newly autopsied cases. Soft tissues of the skull were opened with a crescent-shaped cut which started behind one ear and passed through the vertex to the other ear. The skull bone was sawed and the upper section was removed to allow access to the brain tissue. The brain was extracted and washed with water and was grossly observed without fixation. All cases with more than one aneurysm in the Circle of Willis were classified as multiple aneurysms.

## RESULTS

We studied 425 cadavers including 148 females and 277 males. Fourteen cases (3.29%) had berry aneurysms of the Circle of Willis, including six females and eight males. Two of them (one female and one male) had multiple aneurysms. (Figure 1) depicts the distribution of cases according their age and sex.

In the 12 cases with single aneurysms, location of the aneurysm was at the middle cerebral artery in five (two females and three males), anterior communicating artery in three (one female and two males), internal carotid artery in one (female), posterior communicating artery in one (female) and anterior cerebral artery in two (both female) cases. Seven out of 12 single aneurysms (58.3%) were located at or near a bifurcation of the affected artery (three females and four males) while the remaining five were located in the trunk of the artery (three females and two males). (Figure 2) is a schematic presentation of the location of the 12 single aneurysms.

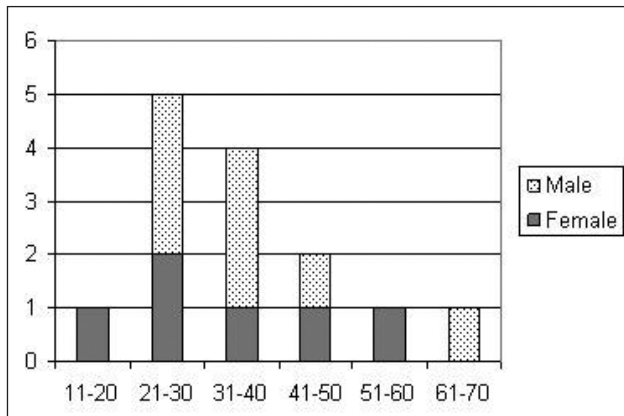


Figure 1: Distribution of cases of berry aneurysms by sex and age.

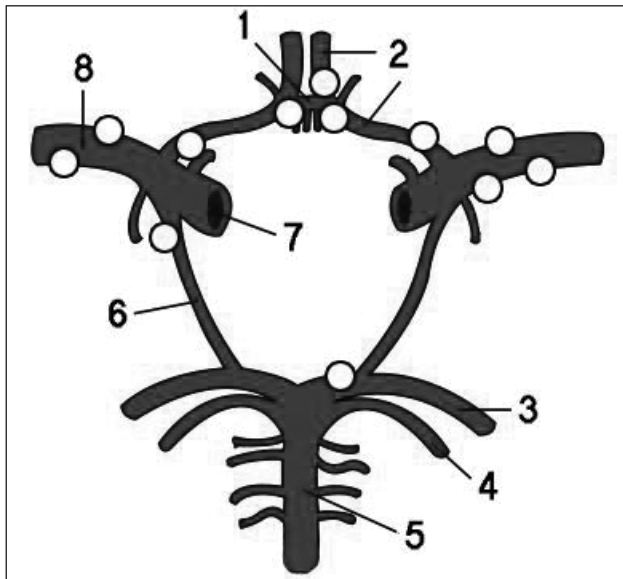


Figure 2: Schematic presentation of the locations of the twelve single aneurysms.

One of the cases with multiple aneurysms was a male from the 41-50 years of age group. The aneurysms were located on his anterior and middle cerebral arteries. The other case with multiple aneurysms was a female from the age group of 31-40 years, who had four aneurysms in her Circle of Willis. Two of the aneurysms resided on middle cerebral artery, one on the anterior communicating artery and one on the anterior cerebral artery.

**DISCUSSION**

Previous studies report that approximately 85% of cerebral aneurysms develop in the anterior part of the Circle of Willis which is in agreement with our findings, where eleven out of twelve single aneurysms were located in anterior part of the Circle

of Willis (91.7%). Our results were roughly in accordance with the previous studies in regards to the tendency of the aneurysms being located at or near the bifurcation of arteries (5). The difference between the proportion of aneurysms located at or near the bifurcation of arteries in our study (58.3%) with that reported in previous trials (80%) could be related to the small number of cases in our study, or because we only studied a general subgroup of cases with berry aneurysms (those with accidental death).

A previous systematic review has shown that the prevalence of intracranial aneurysms is highest in patients aged over 60 and lowest in adults aged less than 40 years (9,12), which is different from what we observed. We believe this difference is due to the different nature of cases included in our study, since most of deaths due to accidents occur in younger adults. Similarly, although the result of meta-analysis of previous autopsy studies dose not allow relating the frequency of intracranial aneurysms to the subjects' sex, our results are deviated toward a higher frequency of aneurysms found in males, which can be justified in regard to the high proportion of males among patients died in accidents in Iran.

Although we excluded subjects with gross intracranial hemorrhage, it is still possible that some of the cases had suffered from minor head trauma during the course of accident that led to their death.

Traumatic intracranial aneurysms are divided into four categories according to the mechanism of injury: following closed head injury, missile injury, penetrating head injury, and iatrogenic injury (18). A clear-cut diagnosis of traumatic aneurysms is only possible by angiography or at autopsy (17). The results of this autopsy study demonstrated the characteristics of berry aneurysms in Iranian population. To our knowledge, this is the first study addressing the anatomical characteristics of berry aneurysm in the Eastern Mediterranean region.

**Acknowledgement**

The authors would like to thank the Farzan Institute for Research and Technology for technical assistance.

**REFERENCES**

1. The International Study of Unruptured Intracranial Aneurysms Investigators. Unruptured intracranial aneurysms--risk of rupture and risks of surgical intervention. International Study of Unruptured Intracranial Aneurysms Investigators. N Engl J Med 339: 1725-1733, 1998

2. Bonita R: Cigarette smoking, hypertension and the risk of subarachnoid hemorrhage: A population-based case-control study. *Stroke* 17: 831-835, 1986
3. Brown RD Jr: Pathogenesis, natural history, and treatment of unruptured intracranial aneurysms. *Mayo Clin Proc* 79: 1572-1583, 2004
4. Connolly ES, Solomon, RA: Management of unruptured aneurysms. In: Le Roux, PD,
5. Kumar V, Cotran RS, Robbins SL. *Robbins basic pathology*. 7th ed. Philadelphia: Saunders, 2003
6. Larson PS, Reisner A, Morassutti DJ, Abdulhadi B, Harpring JE. Traumatic intracranial aneurysms. *Neurosurg Focus* 2000;8:e4
7. Morón F, Benndorf G, Akpek S, Dempsy R, Strother CM. Spontaneous thrombosis of a traumatic posterior cerebral artery aneurysm in a child. *AJNR Am J Neuroradiol* 2005 26:58-60
8. Neil-Dwyer G, Bartlett JR, Nicholls AC. Collagen deficiency and ruptured cerebral aneurysms: A clinical biochemical study. *J Neurosurg* 1983; 59:16-20
9. Rinkel GJE, Djibuti M, Algra A, van Gijn J. Prevalence and risk of rupture of intracranial aneurysms: a systematic review. *Stroke* 1998; 29:251-6
10. Sarti C, Tuomilehto J, Salomaa V, Sivenius J, Kaarsalo E, Narva EV, Salmi K, Torppa J. Epidemiology of subarachnoid hemorrhage in Finland from 1983 to 1985. *Stroke* 1991; 22:848-53
11. Schievink WI: Intracranial aneurysms. *N Engl J Med* 336: 28-40, 1997
12. Shah Q, Friedman J, Mamourian A: Spontaneous resolution of traumatic pseudoaneurysm of the middle meningeal artery. *AJNR Am J Neuroradiol* 26:2530-2532, 2005
13. Stehbens WE: Aneurysms and anatomic variations of cerebral arteries. *Arch Pathol* 75: 45-64, 1963
14. Tan TC, Chan CM, Chiu HM: Traumatic intracranial aneurysm in infancy. *Br J Neurosurg* 15: 137-139, 2001
15. Teunissen LL, Rinkel Gj, Algra A, van Gijn J: Risk factors for subarachnoid hemorrhage: A systematic review. *Stroke* 27: 544-549, 1996
16. Tomasello F, D'Avella D, Salpietro FM, Longo M: Asymptomatic aneurysms. Literature meta-analysis and indications for treatment. *J Neurosurg Sci* 42(1 Suppl 1): 47-51, 1998
17. Türeyen K: Traumatic intracranial aneurysm after blunt trauma. *Br J Neurosurg* 15: 429-431, 2001
18. Ventureyra EC, Higgins MJ: Traumatic intracranial aneurysms in childhood and adolescence. Case reports and review of the literature. *Childs Nerv Syst* 10: 361-379, 2004
19. Wiebers DO, Piepgras DG, Meyer FB, Kallmes DF, Meissner I, Atkinson JL, Link MJ, Brown RD Jr: Pathogenesis, natural history, and treatment of unruptured intracranial aneurysms. *Mayo Clin Proc* 79: 1572-1583, 2004
20. Winn HR, Newell, DW, eds.: *Management of cerebral aneurysms*. Philadelphia: Saunders, 2004: 271-285