

Peripheral Giant Cell Granuloma surgery with diode laser

Authors _Maziar Mir, Masoud Mojahedi, Jan Tunér, Amir Mansour Shirani & Masoud Shabani, Iran, Germany & Sweden

_Laser surgery has many benefits such as maintenance of sterile condition, reduction of bleeding, good possible estimation of cutting depth, precision of cutting, often no need for suturing or bandages, pain reduction, minimally invasive procedure to reduction of patient stress, promotion of wound healing and less scars. Thereby, the patient can often do the routine activities after laser surgery. Many cases have been reported in literature regarding treatment of oral exophytic lesion by laser. In the following case report, we present a treatment Periodontal Peripheral Giant Cell Granuloma (PGCG) without suturing.

_Introduction

PGCG is originated from the periodontal ligament or the periosteum.¹ The lesion is more common in the lower jaw than in the upper jaw and is also more common in females than males.²⁻⁴ Any region of the jaws can be involved by this lesion.^{4,5} Mobility and displacement of the neighboring teeth can occur.⁶ The lesion size varies from about 0,1 cm to 3 cm in most cases.^{5,7}

Fig. 1_PGCG.

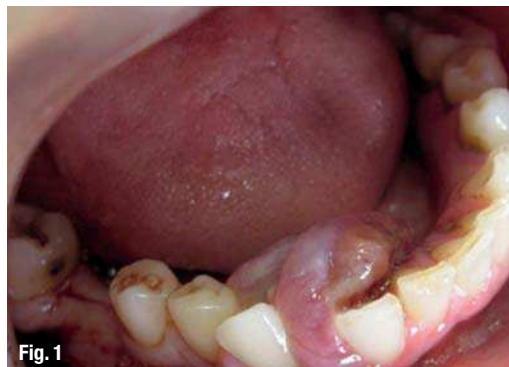

Fig. 1

The etiology is unknown but local irritating factors such as ill-fitting prosthesis, poor restorations, microbial dental plaque, calculus, chronic infection and lack of nutrients may have a role in the etiology. The lesion may be seen in cases of hyperparathyroidism, after periodontal surgery.⁸⁻¹¹ The presence of S-100 positive cells, which are evidence of Langerhans cells or their precursors, and the presence of fibroblasts, endothelial cells, and myofibroblasts point towards a reactive nature of the PGCG.¹²⁻¹⁴ Excision (with scalpel, electrocautery and lasers) and also eliminating any local irritating factors must be considered in the treatment of the lesion. Recurrence rate of the lesions ranges from five to eleven per cent.^{15,5}

_Case report

A 45-year-old female patient with complaints of gingival mass for a period of six months referred for treatment. The lesion was not painful but had bleeding while eating or sometimes even spontaneously.

Medical history

The patient's medical history has shown no systemic medical problems, no allergic reaction, no medicament or drugs and no history of past surgical procedures, so that the patient does need to be referred for medical consultation.

Dental history

Oral and maxillofacial examination of the patient revealed no T.M.J. or myofacial disturbances, no functional or parafunctional habits, class I malocclusion, with poor oral hygiene and multiple caries in the permanent teeth.

Clinical findings

The clinical findings revealed an exophytic lesion in the labial and lingual surfaces of the lower jaw. The lesion was partially firm, red to pink, bleeding while eating or spontaneously, no pain, slightly movable with duration of more than six months, more accumulation of the dental plaque and calculus, gingivitis and pseudopockets in the other sites of both jaws.

X-ray examination

X-ray examination showed no destructive effect such as alveolar bone resorption but slight displacement of the involved teeth. The case was provisionally diagnosed as PGCG and we decided to treat it with a diode laser.

Treatment delivery sequence

After the patient filled in the consent form, the surgery area was anesthetised through infiltration method by two percent lidocaine with Epi 1:100000, 1.8 ml and then a retraction suture was placed in the lesion. In the next step, we defined the controlled area and properly placed the laser warning signs to secure the operating room. Then, we checked the safety for the patient's eye glasses, the patient's guardian eye protection and the assistant's eye protection. After this, we reviewed the patient's information (examination sheet and X-ray, consent form, etc.) and cared for a proper calibration of the laser system (fiber cleaving, beam aiming, and initiation of fiber with articulation paper and test-fire of the laser). The lesion excisional biopsy was started with initiated fiber and the incision was performed with tissue under tension and contact of the hot tip with tissue so that the lesion was separated in the proper way. In the starting of the surgery we used a

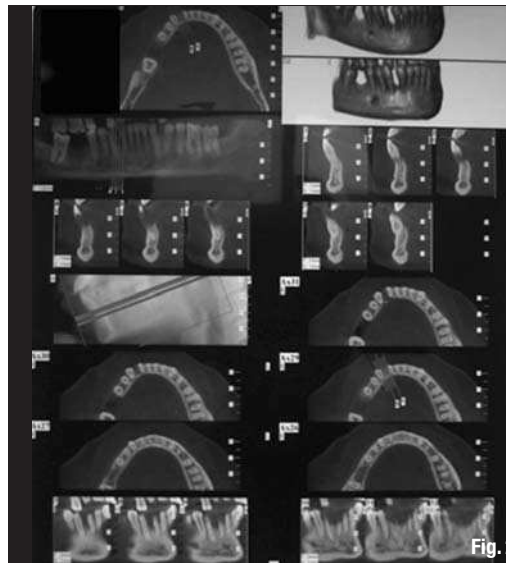


Fig. 2



Fig. 3

diode laser with 980 nm, fiber 400 μ , output power 2 W, CW, contact mode, irradiation time 189 sec., but after gross removal of the lesion we changed the laser setting so that we applied 1W, fiber 400 μ , CW, contact mode, irradiation time 15 sec. per pocket for sulcular debridement of the neighbouring teeth for deep ablation. During the treatment, high volume suction was used to evacuate vapour plume and objectionable odours at the site of operation. During treatment the laser tissue interaction was respected in order to prevent of any unsuitable reaction and the surrounding tissue damage through the progression of the tissue vaporization at the base of the lesion and the patient's reflexes. The moisture gauze was used for prevention of unwanted thermal damage in the adjacent tissue and also the black periosteal elevator was applied for prevention of

Fig. 2_Patients X-ray.

Fig. 3_Laser setting for the first surgery.

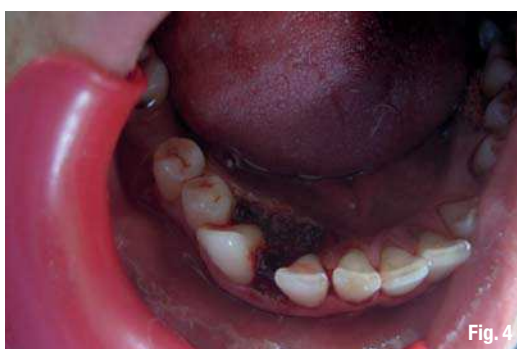

Fig. 4

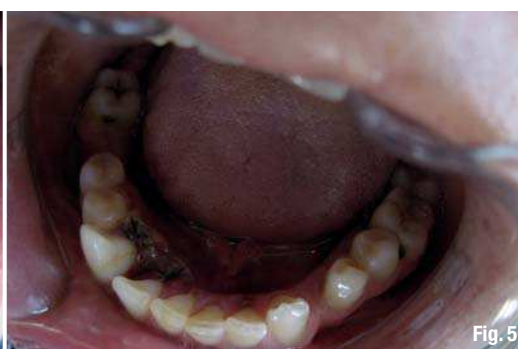

Fig. 5

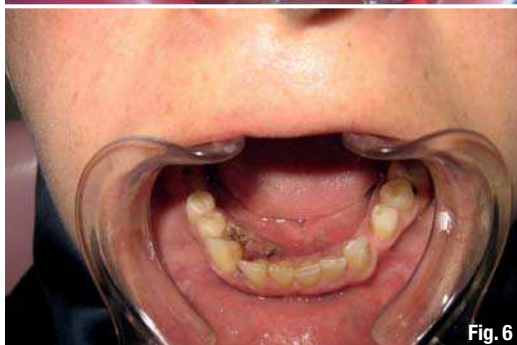

Fig. 6

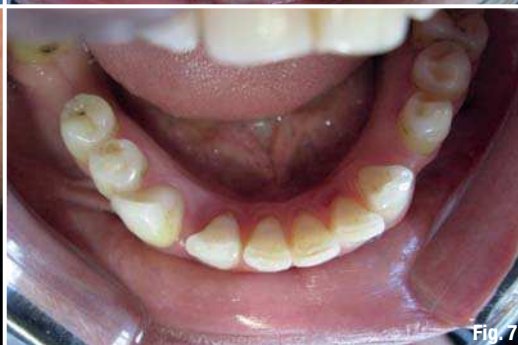

Fig. 7

Fig. 4_Immediately after lasing.

Fig. 5_One day after surgery.

Fig. 6_One week after surgery.

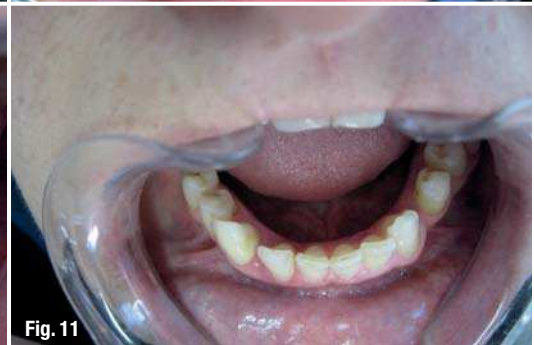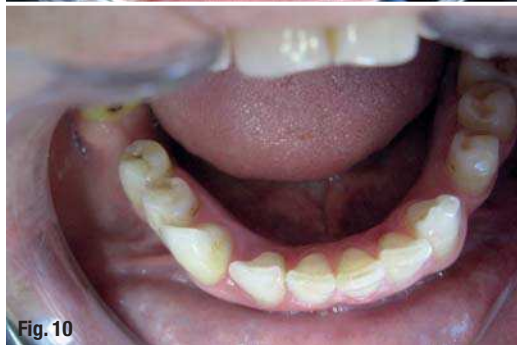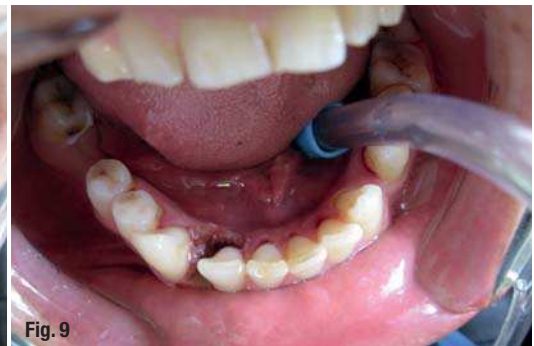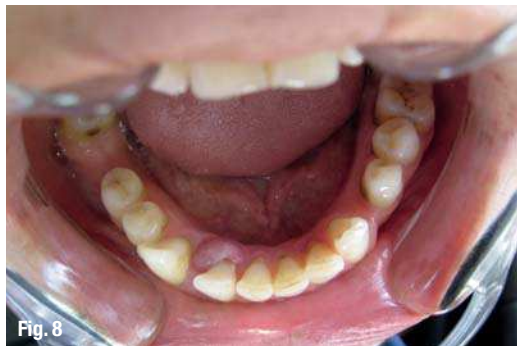Fig. 7_One month after surgery.

Fig. 8_Three months after.

Fig. 9_Immediately after lasing of recurrent PGCG.

Fig. 10_Three months after lasing of recurrent PGCG.

Fig. 11_One year after lasing of recurrent PGCG and perfect treatment.



any thermal conduction in the neighbouring teeth. Removal of carbonization tissue was done by micro-applicator brush soaked in a three per cent hydrogen peroxide solution. The biopsy was sent for laboratory examination. In the post procedural education, the patient was advised to keep the area clean and plaque free with gentle brushing, avoid food and liquids that may cause pain or irritation to the sensitive tissue and taking over-the-counter analgesics as needed. The laser setting was registered in the patient's document for both stages of gross lesion removal and laser sulcular debridement.

Final result

Excellent laser excisional biopsy was observed with no bleeding, no carbonization and no char. The patient did not experience any discomfort and was satisfied.

Follow up

The first visit after laser excisional biopsy was a day after the procedure. The healing process was as expected so that the healing was progressing well and without any swelling or pain. After one week, the patient revisited with no problems in the healing process. Finally, after one month follow up, a successful treatment was observed. After three months follow up the recurrent lesion was observed and renewed lasing of the lesion was performed as the same laser setting and the same treatment delivery sequence. After three months and also after one year the patient was checked again. No recurrence was observed and the neighbouring teeth were vital and intact.

Discussion

In comparison with conventional excisional biopsy procedures (scalpel and suturing), the laser-assisted

excisional biopsy can be performed very fast, with no bleeding, less or no pain, less or no edema and little or no need for analgesics. Because of the size of the lesion, this procedure is traditionally classified as an advanced laser procedure. Full removal of the lesion is very difficult and a recurrent lesion may occur due to insufficient extension of the surgery area. In laser surgery, a larger extension in the surrounding tissue leads to an efficient removal of the lesion so that after one year follow up there was no recurrence.

_Conclusion

As we could see in this case, the diode laser proved to be a powerfull tool for the removal of a periodontal PGCG.

Editorial note: A list of references is available from the publisher.

_contact

laser

Masoud Shabani

Oral Health Department
Official complex of Ardebil University of
Medical Sciences
Daneshgah Street
5618985991, Ardebil, Iran

Tel.: +98 451 5521417
Fax: +98 451 5522196
Mobile: +98 9141511477
m.shabani@arums.ac.ir